Original Paper

Urologia Internationalis

Urol Int
DOI: 10.1159/000445838

Received: November 18, 2015
Accepted after revision: March 30, 2016
Published online: ■■■

Use of Volume Rendered, Maximum Intensity Projection Images to Assess Whether the Medial Calyx Synonymous with the Posterior Calyx

M.G. Pradeepa Maneesh Sinha Venkatesh Krishnamoorthy

Department of Urology, NU Hospitals, Bangalore, India

Key Words
Calyx · Percutaneous nephrolithotomy · Fluoroscopy · Volume rendered · Brodel type · Hodson type

Abstract
Introduction: This paper attempts to verify the anatomical veracity of the belief that in order to enter into a posterior calyx one must aim for the medial calyx during a percutaneous nephrolithotomy (PCNL). ***Methods:*** Volume rendered and maximum intensity projection reconstructions of normal pelvicalyceal systems were assessed in various rotational planes. An experienced urologist decided the appropriate access for PCNL in the upper, interpole and lower calyx on each side. The selected calyx was then viewed on anteroposterior sections to decide whether they were projecting laterally or medially. ***Results:*** Of the 508 calyces studied, the posterior calyx was projecting laterally in 72% and medially in 28%. In the upper calyx, the posterior calyx was projecting laterally in a majority of cases, 94% on the right and 89% on the left. In the right lower calyx, the posterior calyx was pointing laterally in 86%, whereas the distribution on the left was 64%. ***Conclusion:*** Our results refute the belief that the medial calyx is always synonymous with the lateral calyx.

Introduction

Percutaneous nephrolithotomy (PCNL) is a safe and effective procedure for large renal calculi [1]. There are multiple alternatives for the management of large renal stones but none have replaced the PCNL in terms of stone clearance [2].

In order to enter into a posterior calyx, one must aim for the medial calyx during a PCNL. This is a deeply entrenched belief amongst urologists. The anatomical basis of this belief lies in the apparent logic that the kidneys lie on the psoas facing anteromedially, and the symmetrical arrangement of the anterior and posterior calyces results in the posterior calyx pointing medially. The calyces, however, are anything but symmetrical, with varying lengths and angles. In this paper, we set out to test the veracity of the oft-repeated mnemonic – lateral anterior and medial posterior (LAMP) [3].

Advances in CT imaging provide the surgeon with a relatively simple tool to assess basic anatomy. Volume rendering allows projection of 3-dimensional data onto a 2-dimensional screen (fig. 1–3). Maximal intensity projection can be used to remove unwanted tissues so that only the PCS remains.

In this paper, we studied whether posteriorly directed calyces on 3-dimensional CT reconstructions were projecting laterally or medially on coronal maximum intensity projection (MIP) images (fig. 4).

KARGER

E-Mail karger@karger.com
www.karger.com/uin

0042–1138/16/0000–0000$39.50/0

M.G. Pradeepa
Urology Resident, Department of Urology
NU Hospitals
Bangalore – 70, Karnataka (India)
E-Mail dr.pradeep@nutrust.net

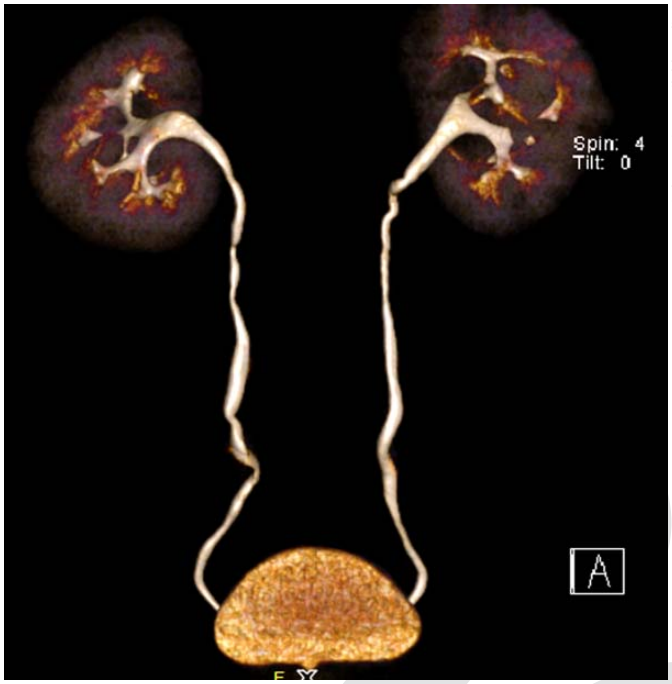

Color version available online

Fig. 1. Volume-rendered 3-dimensional images of PCS on 2-dimensional screen – anteroposterior view.

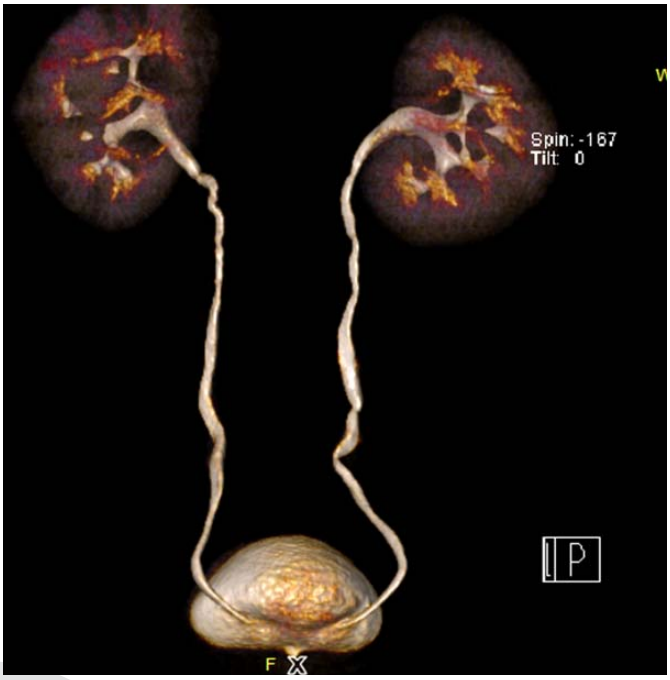

Color version available online

Fig. 3. Volume-rendered 3-dimensional images of PCS on 2-dimensional screen – posterior view.

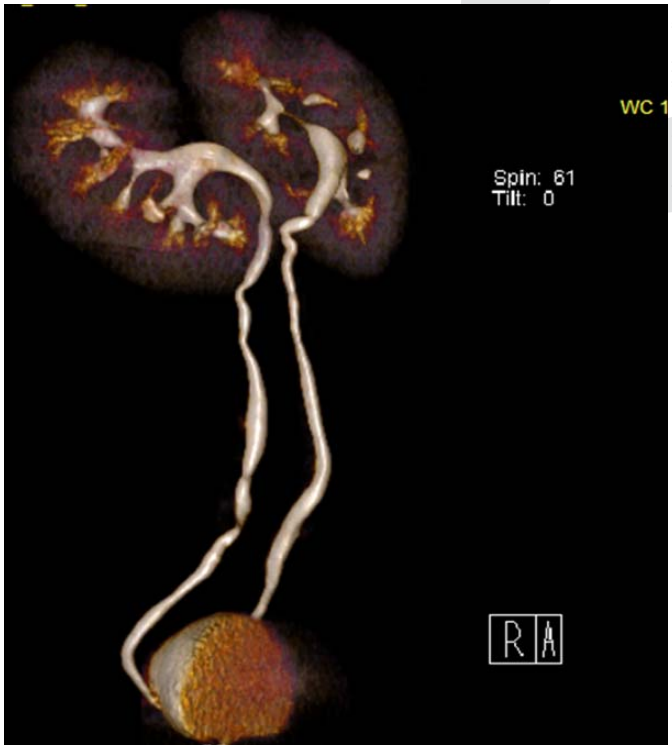

Color version available online

Fig. 2. Volume-rendered 3-dimensional images of PCS on 2-dimensional screen – lateral view.

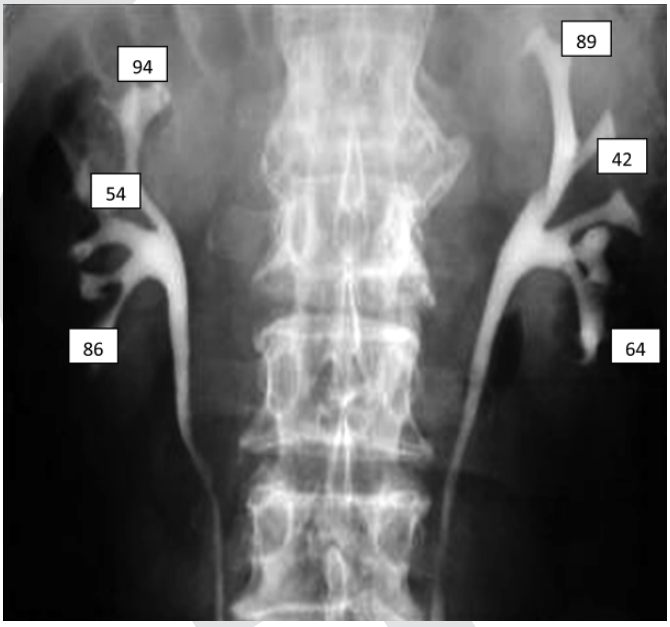

Fig. 4. The numbers depict the percentage of posteriorly directed calyces which were projecting laterally on coronal MIP sections.

Materials and Methods

Image acquisition was done on a General Electronics volume-shuttle CT machine with extended coverage. Reconstruction was done on a workstation equipped with Windows version 4.4 software, and 0.625 mm delayed thin sections were reconstructed on scans done 7–10 min after bolus administration of contrast. These scans were done in the supine position as a part of the evaluation for urolithiasis and also in renal donors as a preoperative evaluation. Renal abnormalities such as tumors, mal-rotation and gross hydronephrosis, which carried a potential for altering the orientation of the PCS were excluded. Studies with poor image quality where the PCS was not delineated adequately were also excluded.

Volume rendered 3-dimensional images were studied in anteroposterior, lateral and various rotational axes by the authors with up to 30 years of experience in PCNL to decide the appropriate posterior calyx to access the PCS if a hypothetical percutaneous access were to be planned. The kidney was then viewed in anteroposterior and coronal MIP sections to decide whether the said calyx would be projecting medially or laterally on a 2-dimensional image, which is usually available to the endourologist on fluoroscopy. The upper, interpole and inferior calyces were analyzed individually on the left as well as the right.

Considering lateral as p1 and medial as p2 group, for 80% power and 95% CI, the sample size required for the adequate power was 47. We included 90 patients who underwent contrast CT scan for the evaluation of urolithiasis (n = 53) and also as a renal donor work-up in normal kidneys (n = 37).

Results

Of the 508 calyces studied in 90 patients, the posterior calyx was projecting laterally in 72% and medially in 28%. In the upper calyx, the posterior calyx was projecting laterally in a majority of cases, 94% on the right and 89% on the left. The relationship was somewhat different in the interpole calyx. On the right, there was an equal probability of the posterior calyx being medial or lateral. On the left, however, the posterior calyx was projecting laterally on the coronal MIP sections in only 35% of kidneys. In the right lower calyx, the posterior calyx was pointing laterally in 86%, whereas on the left it was 64% (fig. 1).

Discussion

The question every urologist asks himself before a PCNL is – Which calyx do I puncture? As per traditional teaching, the medial calyx should be accessed. Practical experience to the contrary prompted us to question this adage. The availability of good quality images made it very easy for us to evaluate renal anatomy.

While it would have been ideal to study stone bearing kidneys in the prone position and plan appropriate puncture, we were constrained by the practical and ethical concerns about change in the usual clinical practice. We, therefore, chose to study the anatomy of kidneys in CT scans done for urolithiasis and also for unrelated indications in the usual supine position. There is, however, no reason to believe that there would be a significant alteration in the renal orientation after stone formation, and the relationships seen in this study should hold true for all stone bearing kidneys. Sengupta et al. [4] have confirmed that there is no clinically significant difference in the orientation of the kidneys in the supine and prone positions.

Our results, at the least, question the veracity of the belief that the medial calyx is necessarily the posterior calyx. In the upper calyx, the reverse is true in the majority of cases and we would recommend a lateral puncture as the first choice. Our data also support choosing the lower lateral calyx for access on the right. On the left, the results in the lower calyx were equivocal. These results seem to suggest a slightly different orientation of the right and left kidneys and corroborate Kaye and Reinke's findings that the Brodel type of kidney with the posterior calyces pointing laterally was more common on the right and the reverse Hodson type was more common on the left [5–7].

Moving from the inferior most lower calyx upward, Miller et al. [8] have numbered the lower pole calyces as 1, 2 and 3. They conclude that the second calyx would be appropriate for access in 92% of lower pole calyces. The authors did not report a difference in orientation in the left and right kidneys. Our results suggest a less extreme relationship in the lower pole. The medial most calyx invariably is also the most inferior and corresponds to calyx 1 in Miller's study. The lateral calyx, which would correspond most commonly to calyx 2 would be appropriate for access in 86% on the right and 64% on the left.

Another important aspect of Miller's study was that the primary plane of the calyces was anteroposterior in the lower pole and mediolateral in the upper pole. We would disagree with their conclusion that any calyx in the upper pole is suitable for puncture. In order to remain in the line of axis of the calyx, one would have to puncture through the paravertebral muscles. We, therefore, believe that this orientation would strongly argue against accessing the medial calyx in the upper pole, a fact corroborated by our results.

In the current scenario, 2-dimensional fluoroscopy remains the most common imaging modality for the PCNL puncture [9]. Fluoroscopic findings described to identify the posterior calyx include calyceal shortening and medial movement of the posterior calyx on changing from 0^0 to an end on view. However, these are not universally useful. During the course of the study, we were convinced that the future of PCNL access lies in 3-dimensional imaging. Authors have reported the feasibility of both ultrasound and CT guided punctures [10, 11]. Until these modalities come into common use, the debate on the calyx of choice will remain relevant.

In our practice, we preferentially aim for the lateral upper calyx and we have been successfully able to enter the posterior calyx in majority of our PCNLs. However this has resulted in the majority of our access tract being supracostal [12].

Conclusion

Our results strongly refute the wisdom of blind dependence on a mnemonic which has little evidence support. Aiming for the lateral calyx will result in the correct access in the large majority of calyces. However, the variability evident in our results mandates that the surgeon makes an individual choice in each calyx.

Financial Supports

None.

Disclosure Statement

None.

References

1 Wang K, Zhang P, Xu X, Fan M: Ultrasonographic versus fluoroscopic access for percutaneous nephrolithotomy: a meta-analysis. Urol Int 2015;95:15–25.
2 Zheng C, Xiong B, Wang H, Luo J, Zhang C, Wei W, Wang Y: Retrograde intrarenal surgery versus percutaneous nephrolithotomy for treatment of renal stones >2 cm: a meta-analysis. Urol Int 2014;93:417–424.
3 Gupta M, Ost MC, Shah JB, McDougall EM, Smith AD: Chapter 46 – Percutaneous Management of the Upper Urinary Tract, ed 9. Campbell-Walsh Urology, 2007.
4 Sengupta S, Donnellan S, Vincent JM, Webb DR: CT analysis of caliceal anatomy in the supine and prone positions. J Endourol 2000;14:555–557.
5 Kaye KW, Reinke DB: Detailed caliceal anatomy for endourology. J Urol 1984;132:1085–1088.
6 Brodel M: The intrinsic blood vessels of the kidney and their significance in nephrostomy. Hopkins Hosp Bull 1901;12:10.
7 Hodson J: The lobar structure of the kidney. Br J Urol 1972;44:246–261.
8 Miller J, Durack JC, Sorensen MD, Wang JH, Stoller ML: Renal calyceal anatomy characterization with 3-dimensional in vivo computerized tomography imaging. J Urol 2013;189:562–567.
9 Park S, Pearle MS: Imaging for percutaneous renal access and management of renal calculi. Urol Clin North Am 2006;33:353–364.
10 Matlaga BR, Shah OD, Zagoria RJ, et al: Computerized tomography guided access for percutaneous nephrostolithotomy. J Urol 2003;170:45–47.
11 Andonian S, Scoffone CM, Louie MK, Gross AJ, Grabe M, Daels FP, Shah HN, de la Rosette JJ; CROES PCNL Study Group: Does imaging modality used for percutaneous renal access make a difference? A matched case analysis. J Endourol 2013;27:24–28.
12 Sinha M, Krishnappa P, Subudhi SK, Krishnamoorthy V: Supracostal percutaneous nephrolithotomy: a prospective comparative study. Indian J Urol 2016;32:45–49.